

Radiology Quiz

R. Rajeshkannan

A 75 yr old female with no known co morbidities has come with complaints of diffuse abdominal pain, vomiting and constipation of 5 days duration. She also has pain in the right leg. CT axial and coronal reconstruction images are given. What is the diagnosis?

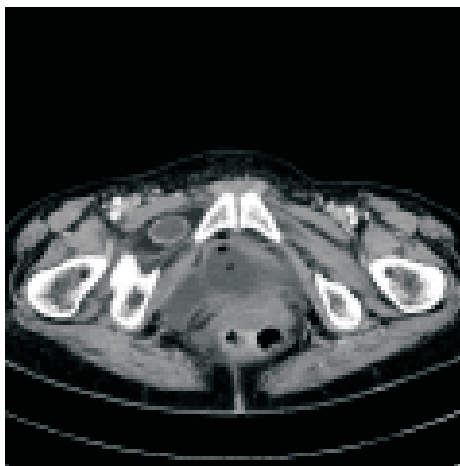

Fig 1

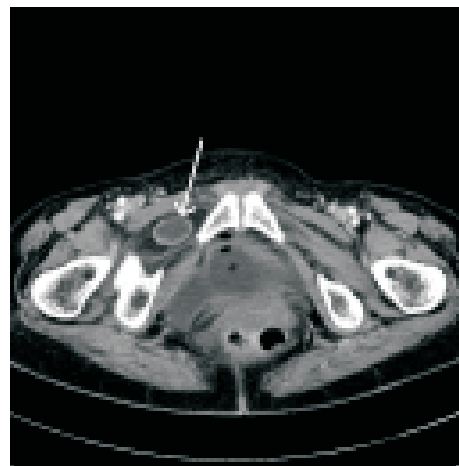


Fig 1a

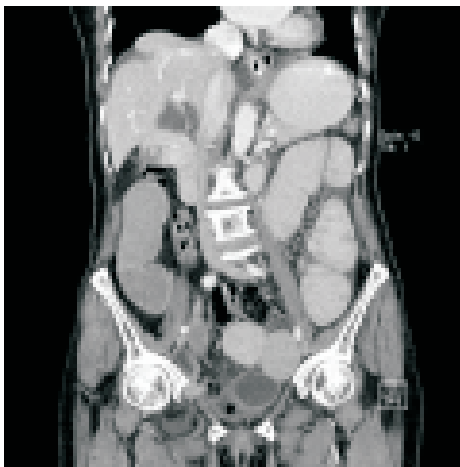

Fig 2

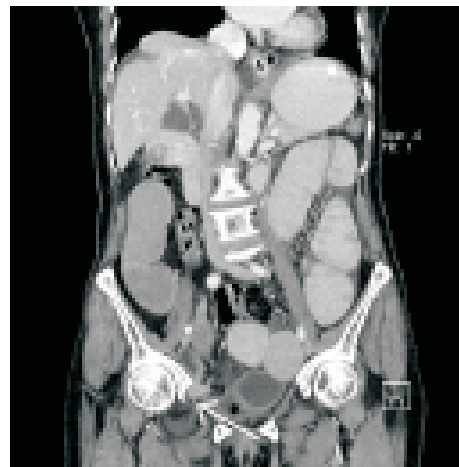

Fig 2a

Answer on Page 39